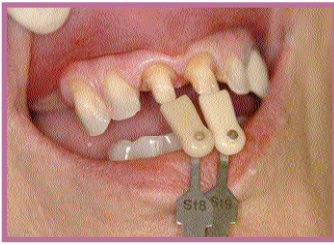
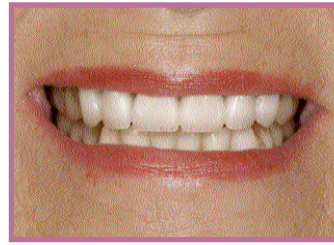

# Photo Checklist for Lab Communication of Anterior Cases

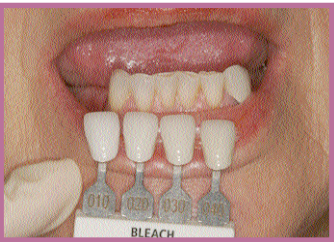For lab communication of anterior cases we recommend the following images of provisionals:



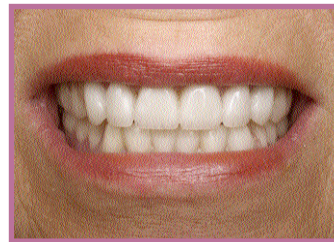
- 1. Stump shades**
- for all-ceramic restorations



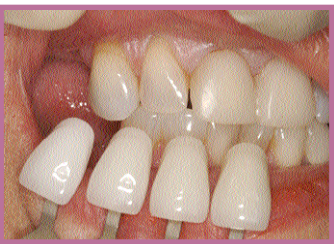- 6. Provisionals - nose-to-chin, relaxed smile**
- shows relationship of upper smile line to lower lip line



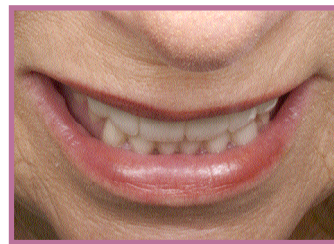- 2. Closest matching shade guide next to teeth -**
- guide numbers visible




- 7. Provisionals - nose-to-chin, high smile**
- shows visible gingival areas



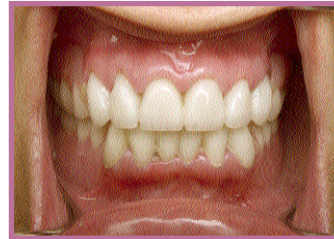- 3. Close-up of adjacent teeth**
- to show surface texture and luster



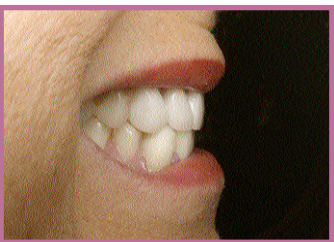- 8. Provisionals - smile head tipped down slightly** (with patient sitting, shoot down from above)
- shows the relationship of arch form to lower lip
  - especially good for reviewing anterior pontics



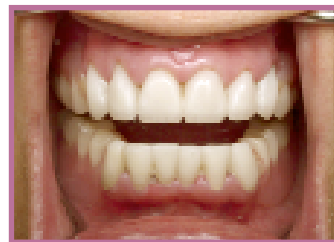
- 4. Provisionals - full face smiling**
- have patient sit upright or stand
  - pictures should be taken at a right angle, with patient's head straight
  - natural smile, not forced



- 9. Provisionals - close-up, lips retracted with teeth in maximum intercuspation**
- shows front-to-back progression



- 5. Provisionals - profile, close-up**
- shows the upper incisal edge position to inner vermillion border of lower lip



- 10. Provisionals - close-up, lips retracted with teeth apart**
- shows incisal silhouette